

Acoustic Neuroma detected on 3T MRI

By Albert Zilkha M.D. & Alain Zilkha M.D.

Acoustic neuromas (schwannomas) are slow-growing benign tumors arising from the sheath (covering) of the eighth cranial nerve of the brain. Tumor size varies from 2mm. to several centimeters. Symptoms include tinnitus (ringing in the ear), vertigo (dizziness) and/or hearing loss. These tumors account for 5 to 10 percent of intracranial neoplasms in adults.

If a patient has any of these symptoms and neurological tests are positive, MRI is the study of choice to identify these tumors. MRI is safe and fast. It provides highly detailed images of these tumors. MRI has tremendous soft tissue resolution. Images are studied in multiple planes.

On a normal MRI of the brain, two nerves are seen in the internal auditory canal (Image 1 right side, arrows). These two structures are the seventh and eighth cranial nerves. In a patient with an acoustic neuroma, a mass is seen

(Image 1 left side, arrow). When this patient is given gadolinium, the tumor lights up brightly (Image 2 left side, arrow). If a patient has their study on 3T MRI, small tumors within the canal are clearly seen. The 3T MRI is the most powerful MRI available and this tumor can even be seen on studies performed without gadolinium (Image 3 right side, arrow).

There are several treatments for acoustic neuromas including surgery and radiation therapy. Some patients may be observed clinically and get follow-up MRIs to detect tumor growth.

At Zilkha Radiology, patients have their studies performed on 3T ultra high field MRI scanners. This is the only type of MRI we have and they are available in our East Islip and West Islip offices. We do not believe in lower strength MRIs with strengths at 1.5T or 0.3T. If you are scheduled for an MRI, make sure it is a 3T MRI. You deserve it.

Besides MRI, we have PET-CT, 128-slice CT scanner with radiation dose

reduction technology, coronary artery CTA, cardiac CTA, CT cardiac scoring, CT angiography, virtual colonoscopy, CT urograms, digital mammo, ultrasound, digital X-ray, nuclear medicine, fluoroscopy (upper GI, barium enemas, hysterosalpingograms), IVPs and DEXA scans. Zilkha Radiology also offers ultrasound and MRI guided biopsies including breast and thyroid biopsies. The facility is accredited to perform monitored anesthesia by Board-Certified Anesthesiologists.

Dr. Albert Zilkha served as Professor of Clinical Radiology at the State University of New York at Stony Brook School of Medicine.

The offices of Zilkha Radiology are conveniently located next to major parkways. The offices are open from 7 a.m. to 8 p.m. Monday through Friday. On Saturday, the office hours are from 7 a.m. to 3 p.m. Call 631-277-1600 or visit zilkharadiology.com.

IMAGE 1

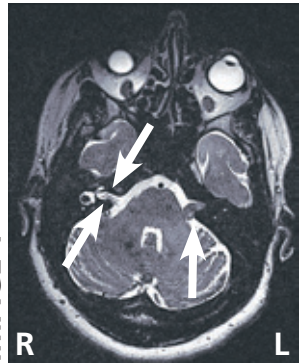


IMAGE 2

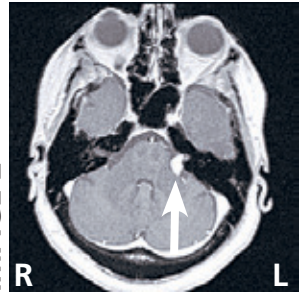


IMAGE 3

